VIDEO CASE REPORT

A novel approach for endoscopic submucosal dissection: scissors versus electricity

Sergey V. Kantsevoy, MD, PhD,[1,2] Shira Levihim, PA,[1] Deborah Pennington, MSN, RN, CGRN,[1] Amit Raina, MD[1]

EMR and endoscopic submucosal dissection (ESD) are widely used for removal of premalignant and malignant lesions of the GI tract.[1-3] Currently used polypectomy snares and available ESD knives use electric energy for resection of GI tract lesions.[4-6]

SB Knives (Olympus America, Center Valley, Pa, USA) and the Clutch Cutter (Fujifilm, Tokyo, Japan) have recently become available in the United States.[7-11] Although these devices have 2 branches and resemble scissors in appearance, their branches are not sharp and cannot mechanically cut tissues. Instead, both SB Knives and the Clutch Cutter use electric energy similarly to other available electrosurgical ESD knives.

Unfortunately, electric energy causes collateral damage to adjacent tissues, resulting in postprocedural pain, postpolypectomy syndrome, and delayed adverse events (tissue necrosis, bleeding, and perforation).[12-17] To eliminate collateral tissue damage by electric current, previous publications have advocated the use of "cold" snares for removal of small colonic polyps.[18-20]

We describe colonic ESD with recently developed endoscopic monopolar scissors (Ensizor; Slater Endoscopy, Miami Lakes, Fla, USA), which uses "cold" tissue cutting instead of "hot" dissection with electric current.

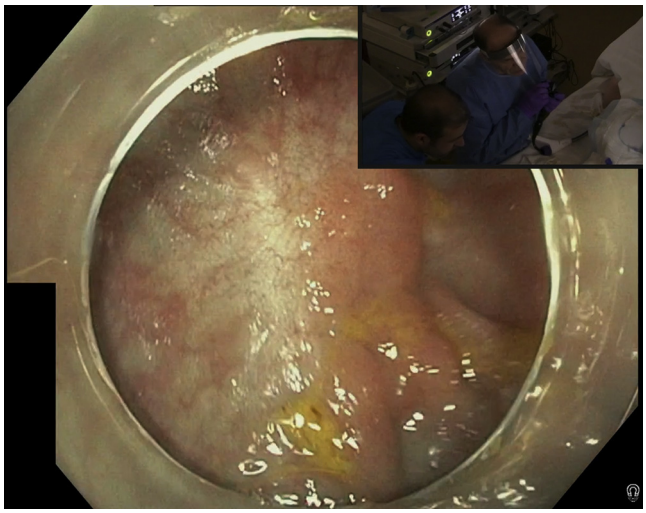

Figure 1. A sessile, flat (IIa, Kudo IIIs) descending colon polyp partially removed during previous colonic EMR.

A 63-year-old man was referred for endoscopic resection of a difficult (sessile, flat, IIa, Kudo IIIs, 20 mm) descending colon polyp that had been partially removed during

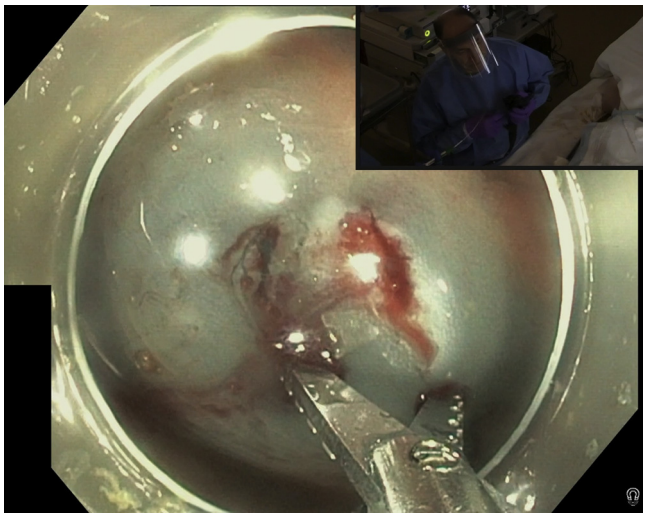

Figure 2. A circumferential mechanical incision around the polyp started with endoscopic scissors.

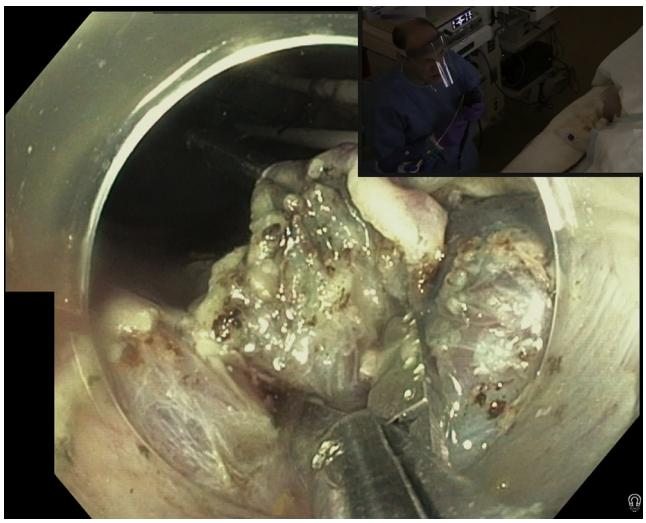

Figure 3. The polyp is attached to the fore-balloon of the retraction device with endoscopic clip and pulled in an oral direction, exposing extensive fibrosis in the submucosal space. Endoscopic submucosal dissection was performed by cutting fibrotic tissue with scissors.

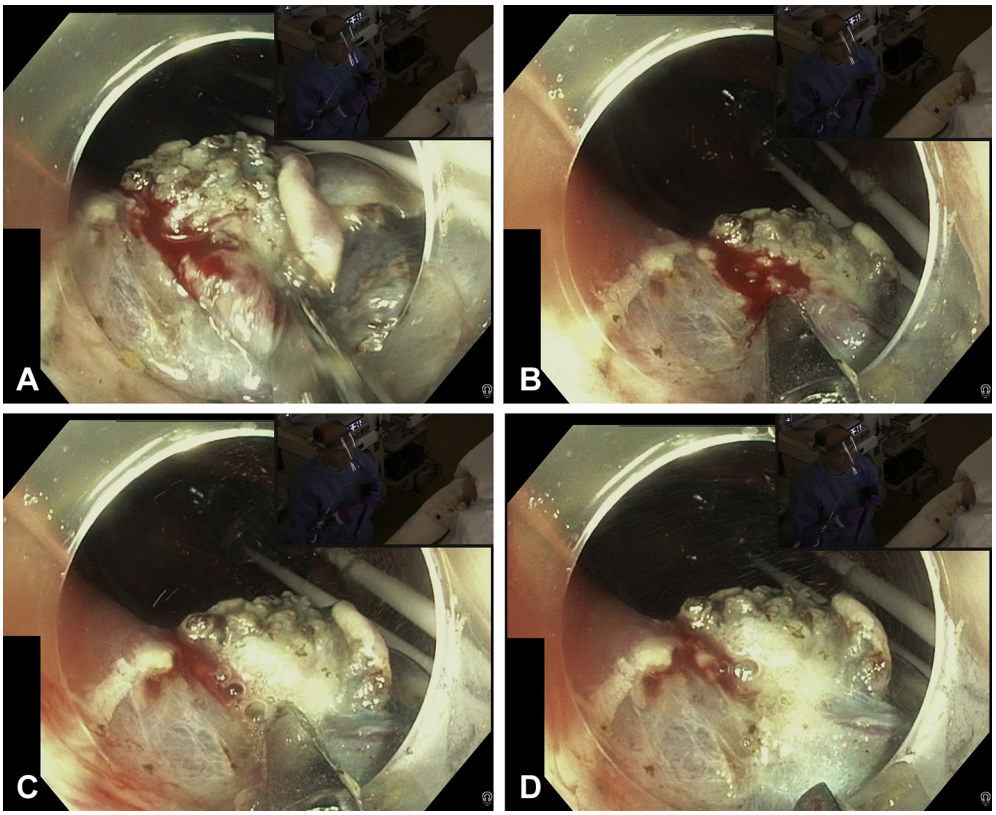

Figure 4. Hemostasis during endoscopic submucosal dissection is achieved by use of the electrocautery function of the scissors. **A,** Active bleeding from a large submucosal vessel. **B,** Tip of the scissors is placed in contact with the bleeding vessel. **C,** Bleeding vessel is coagulated by the scissors. **D,** Bleeding is completely stopped after application of electrocautery through the scissors.

Figure 5. The polyp is removed en bloc.

Figure 6. Overstitch endoscopic suturing device is delivered to the endoscopic submucosal dissection site through the DiLumen retractor.

previous colonic EMR (Fig. 1; Video 1; available online at www.VideoGIE.org). After submucosal injection, a circumferential mechanical incision around the polyp was made with endoscopic scissors (Fig. 2). The polyp was attached to the fore-balloon of a DiLumen retraction device (Lumendi, Westport, Conn, USA) with an endoscopic clip (Resolution 360; Boston Scientific, Natick, Mass, USA). The fore-balloon was pushed in an oral direction, exposing extensive fibrosis in the submucosal space. ESD was performed by cutting the fibrotic tissue with scissors (Fig. 3), followed by placement of a second clip for additional traction.

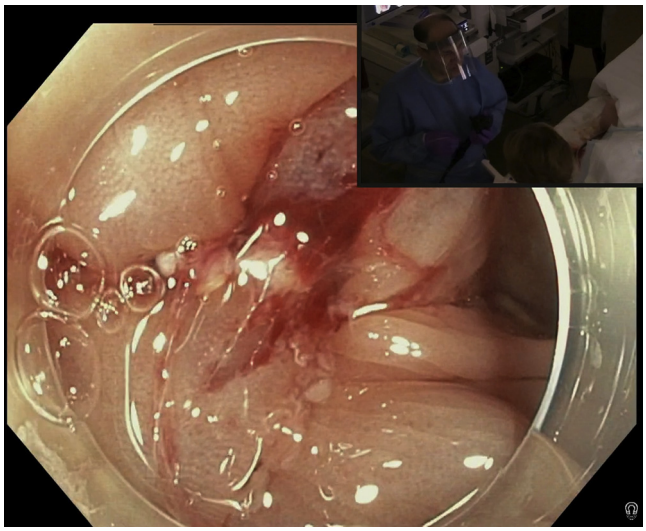

Figure 7. Mucosal defect after lesion removal is completely closed with 1 continuous suture.

Hemostasis during ESD was achieved by touching the blood vessels with the tip of the monopolar scissors and using the electrocautery function of the Ensizor scissors in soft coagulation mode (50 W, effect 2) (Fig. 4). The polyp was removed en bloc (Fig. 5), and the mucosal defect post lesion removal was closed with 1 continuous suture (Figs. 6 and 7) by use of the Overstitch endoscopic suturing device (Apollo Endosurgery, Austin, Tex, USA). The patient was discharged home after the procedure. Pathologic examination revealed tubular adenoma and confirmed R0 resection with negative margins.

In conclusion, newly designed endoscopic scissors allow ESD and effective endoscopic hemostasis. ESD with mechanical scissors instead of the currently used electrosurgical knives eliminates collateral damage of tissues adjacent to the plane of dissection, preserving the margins of the specimen for histologic assessment and preventing postprocedural pain, postpolypectomy syndrome, and delayed adverse events (tissue necrosis, bleeding, and perforation). The use of a traction device facilitates ESD and serves as a conduit for endoscopic suturing closure of large mucosal defects after lesion removal.

DISCLOSURE

Dr Kantsevoy is a consultant for Apollo Endosurgery, Aries, Endocages, LumenDi, Medtronic, Olympus, and Vizballoons; is a co-founder of Apollo Endosurgery and Endocages; is a shareholder in Apollo Endosurgery; is on LumenDi advisory board; is in active litigation with LumenR; and an equity holder in Endocages, LumenDi, Slater Endoscopy and Vizballoons. All other authors disclosed no financial relationships relevant to this publication.

ACKNOWLEDGEMENT

The authors would like to thank Slater Endoscopy (Miami Lakes, Fla, USA) for providing Ensizor endoscopic monopolar scissors for this procedure.

Abbreviation: ESD, endoscopic submucosal dissection.

REFERENCES

1. Fujiya M, Tanaka K, Dokoshi T, et al. Efficacy and adverse events of EMR and endoscopic submucosal dissection for the treatment of colon neoplasms: a meta-analysis of studies comparing EMR and endoscopic submucosal dissection. Gastrointest Endosc 2015;81:583-95.
2. Cao Y, Liao C, Tan A, et al. Meta-analysis of endoscopic submucosal dissection versus endoscopic mucosal resection for tumors of the gastrointestinal tract. Endoscopy 2009;41:751-7.
3. Kobayashi N, Yoshitake N, Hirahara Y, et al. Matched case-control study comparing endoscopic submucosal dissection and endoscopic mucosal resection for colorectal tumors. J Gastroenterol Hepatol 2011;27:728-33.
4. Kantsevoy SV, Adler DG, Conway JD, et al. Endoscopic mucosal resection and endoscopic submucosal dissection. Gastrointest Endosc 2008;68:11-8.
5. ASGE Technology Committee; Maple JT, Abu Dayyeh BK, Chauhan SS, et al. Endoscopic submucosal dissection. Gastrointest Endosc 2015;81:1311-25.
6. ASGE Technology Committee; Tokar JL, Barth BA, Banerjee S, et al. Electrosurgical generators. Gastrointest Endosc 2013;78:197-208.
7. Homma K, Otaki Y, Sugawara M, et al. Efficacy of novel SB knife Jr examined in a multicenter study on colorectal endoscopic submucosal dissection. Dig Endosc 2012;24:117-20.
8. Yamashina T, Takeuchi Y, Nagai K, et al. Scissor-type knife significantly improves self-completion rate of colorectal endoscopic submucosal dissection: single-center prospective randomized trial. Dig Endosc 2017;29:322-9.
9. Takasago T, Kuwai T, Yamaguchi T, et al. Endoscopic submucosal dissection with a scissors-type knife for post-EMR recurrence tumor involving the colon diverticulum. VideoGIE 2017;2:211-2.
10. Ge PS, Thompson CC, Aihara H. Endoscopic submucosal dissection of a large cecal polyp using a scissor-type knife: implications for training in ESD. VideoGIE 2018;3:313-5.
11. Yoshida N, Inada Y, Murakami T, et al. Colorectal endoscopic submucosal dissection for a lesion on the dentate line area resected with a scissor-type knife. VideoGIE 2018;3:223-5.
12. Harada H, Suehiro S, Murakami D, et al. Clinical impact of prophylactic clip closure of mucosal defects after colorectal endoscopic submucosal dissection. Endosc Int Open 2017;5:E1165-71.
13. Ikezawa K, Michida T, Iwahashi K, et al. Delayed perforation occurring after endoscopic submucosal dissection for early gastric cancer. Gastric Cancer 2011;15:111-4.
14. Miyahara K, Iwakiri R, Shimoda R, et al. Perforation and postoperative bleeding of endoscopic submucosal dissection in gastric tumors: analysis of 1190 lesions in low- and high-volume centers in Saga, Japan. Digestion 2012;86:273-80.

15. Oka S, Tanaka S, Kanao H, et al. Current status in the occurrence of postoperative bleeding, perforation and residual/local recurrence during colonoscopic treatment in Japan. Dig Endosc 2010;22:376-80.
16. Conio M, Repici A, Demarquay JF, et al. EMR of large sessile colorectal polyps. Gastrointest Endosc 2004;60:234-41.
17. Piraka C. Cold snare resection of large duodenal and colonic polyps. Gastroenterol Hepatol (N Y) 2018;14:539-41.
18. Tachikawa J, Chiba H, Kuwabara H, et al. Successful 2-channel cold snare polypectomy of a colorectal lesion involving the appendiceal orifice. VideoGIE 2018;3:279-80.
19. Chang LC, Shun CT, Hsu WF, et al. Risk of delayed bleeding before and after implementation of cold snare polypectomy in a screening colonoscopy setting. Endosc Int Open 2019;7:E232-8.
20. Piraka C, Saeed A, Waljee AK, et al. Cold snare polypectomy for non-pedunculated colon polyps greater than 1 cm. Endosc Int Open 2017;5:E184-9.

Institute for Digestive Health and Liver Diseases, Mercy Medical Center (1); University of Maryland School of Medicine (2), Baltimore, Maryland, USA.

If you would like to chat with an author of this article, you may contact Dr Kantsevoy at skan51@hotmail.com.

https://doi.org/10.1016/j.vgie.2019.05.010